



CASE REPORT

Repetitive syncopal episodes in a child with documented ventricular tachycardia, early repolarization pattern in leads I and aVL, Brugada syndrome, and fever

Humberto Rodríguez-Reyes MD, FACC, FHRS¹  | Andrés Pérez-Riera MD²  |
 Brenda Lucía López MD¹ | María del Refugio Salinas MD¹ | Luz Ma Mayela Muñoz MD¹ |
 Cesar Ivan Laguna MD¹ | Nikus Kjell MD³

¹Sociedad Cardiovascular y Arritmias (SOCAyA), Aguascalientes, México, o

²Laboratório de Metodologia de Pesquisa e Escrita Científica, Faculdade de Medicina do ABC, São Paulo, Brazil

³Heart Center, Tampere University Hospital and Faculty of Medicine and Health Technology, Tampere University, Tampere, Finland

Correspondence

Rodríguez Reyes Humberto, Sociedad Cardiovascular y Arritmias (SOCAyA), Rep. de Argentina 123, Fracc. Las Américas, CP 20230, Aguascalientes, México.
 Email: humbertorodriguezr@hotmail.com

Abstract

We present a small child with febrile peaks and syncopal episodes secondary to ventricular tachycardia, in whom it was eventually possible to demonstrate the Brugada Syndrome with a special presentation in the ECG; early repolarization pattern in lead I and aVL and Brugada pattern during fever in V1-V2. This is, to our knowledge, the first case with this special ECG presentation in a small child.

KEYWORDS

Brugada syndrome, early repolarization, fever, syncope, ventricular tachycardia

1 | INTRODUCTION

Brugada syndrome (BrS) is an inherited arrhythmic disorder that may result in sudden cardiac death (SCD), and it is estimated to account

for 4% of all SCDs and for 20% of all SCDs in patients with an apparently normal heart. The first arrhythmic event (AE) typically occurs in male patients aged 40 to 50 years, but rarely during childhood. According to the Survey on Arrhythmic Events in Brugada Syndrome

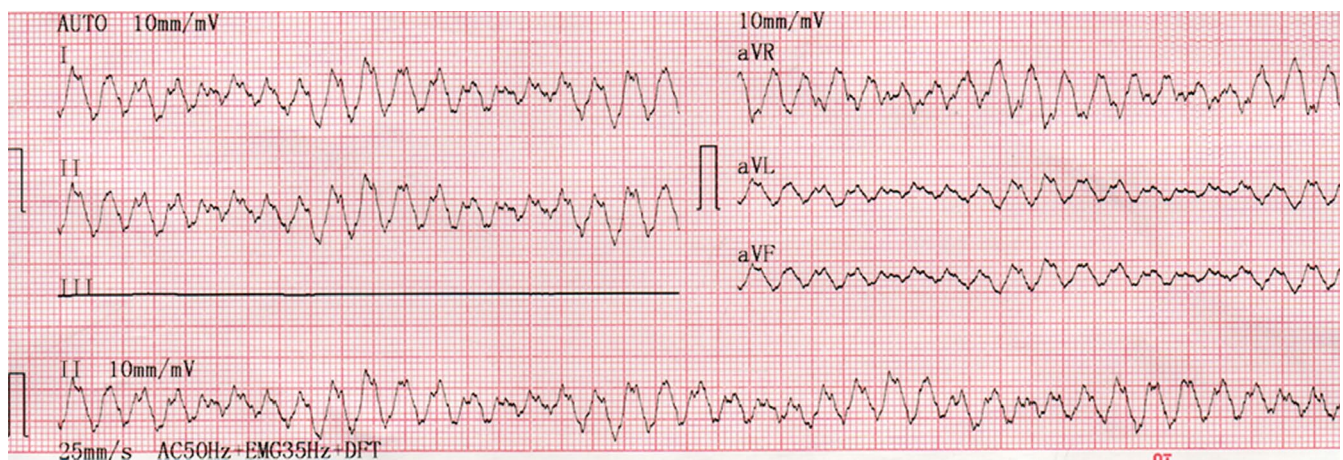


FIGURE 1 Ventricular tachycardia

This is an open access article under the terms of the Creative Commons Attribution-NonCommercial-NoDerivs License, which permits use and distribution in any medium, provided the original work is properly cited, the use is non-commercial and no modifications or adaptations are made.

© 2019 The Authors. *Annals of Noninvasive Electrocardiology* published by Wiley Periodicals, Inc.

(SABRUS) data, in only 4.3% the first AE occurs in the pediatric population (Milman et al., 2017). The Brugada syndrome ECG is much more prevalent in patients with fever than in afebrile controls (Michowitz et al., 2018).

We present a small child with febrile peaks and syncopal episodes, in whom it was eventually possible to demonstrate the Brugada syndrome with a special presentation in the ECG: early repolarization pattern in leads I and aVL and Brugada pattern during fever in V1-V2.

2 | CASE REPORT

Our case is a 2-year 6 months old boy, weight 14 kg with a family history of diabetes mellitus and hypertension in paternal grandparents and uncles. A cousin had arrhythmias of unknown origin, but without syncope or other alarming symptoms. There was no history of sudden death in the first-degree relatives.

At 1 year of age, he presented with a sudden episode (3 hr) of flaccidity, diaphoresis, cyanosis, polypnea, with spontaneous

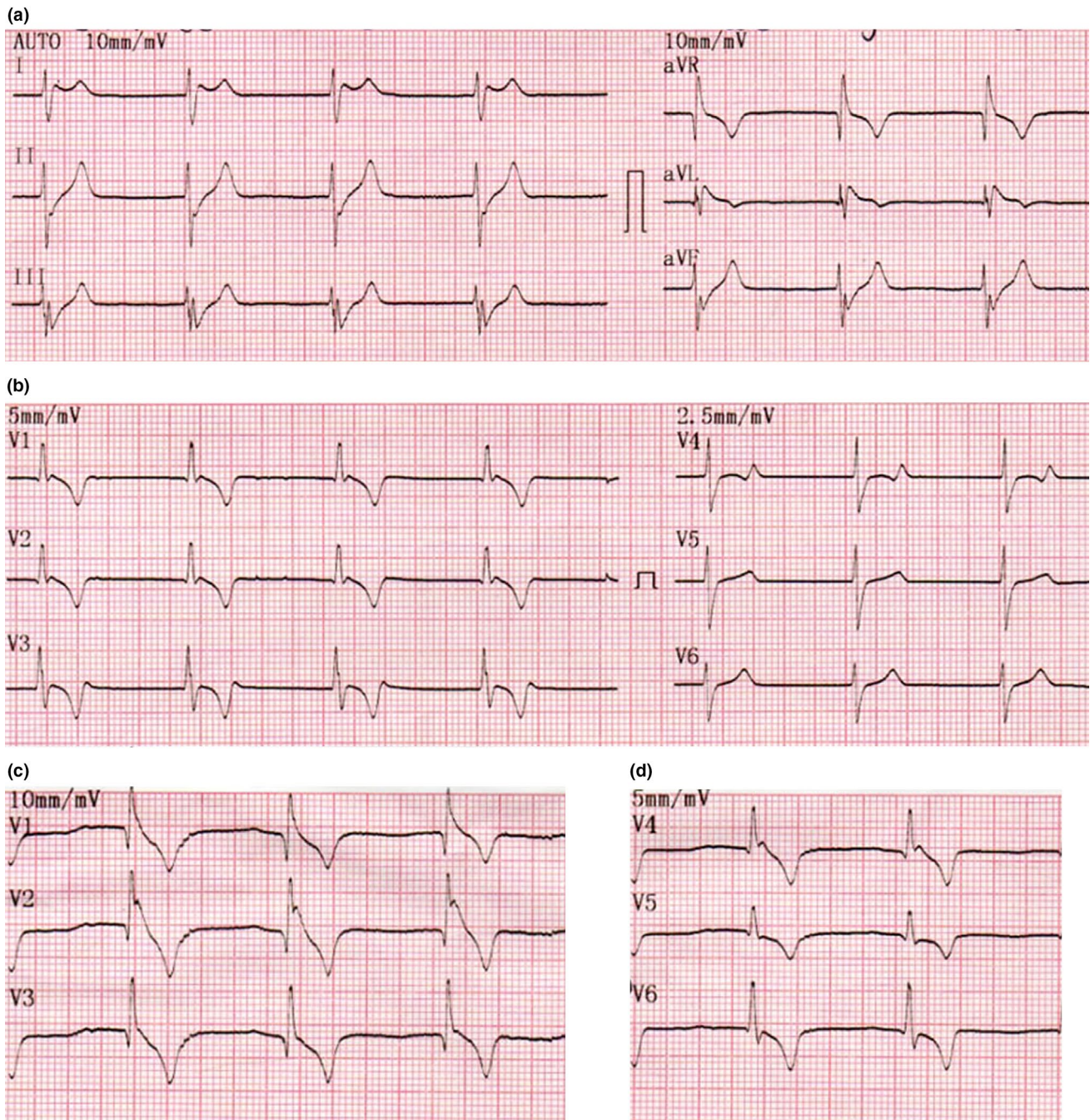


FIGURE 2 Nodal rhythm with high precordial leads (marked as leads V1-V6 below), note J-wave elevation in I, aVL and high V2

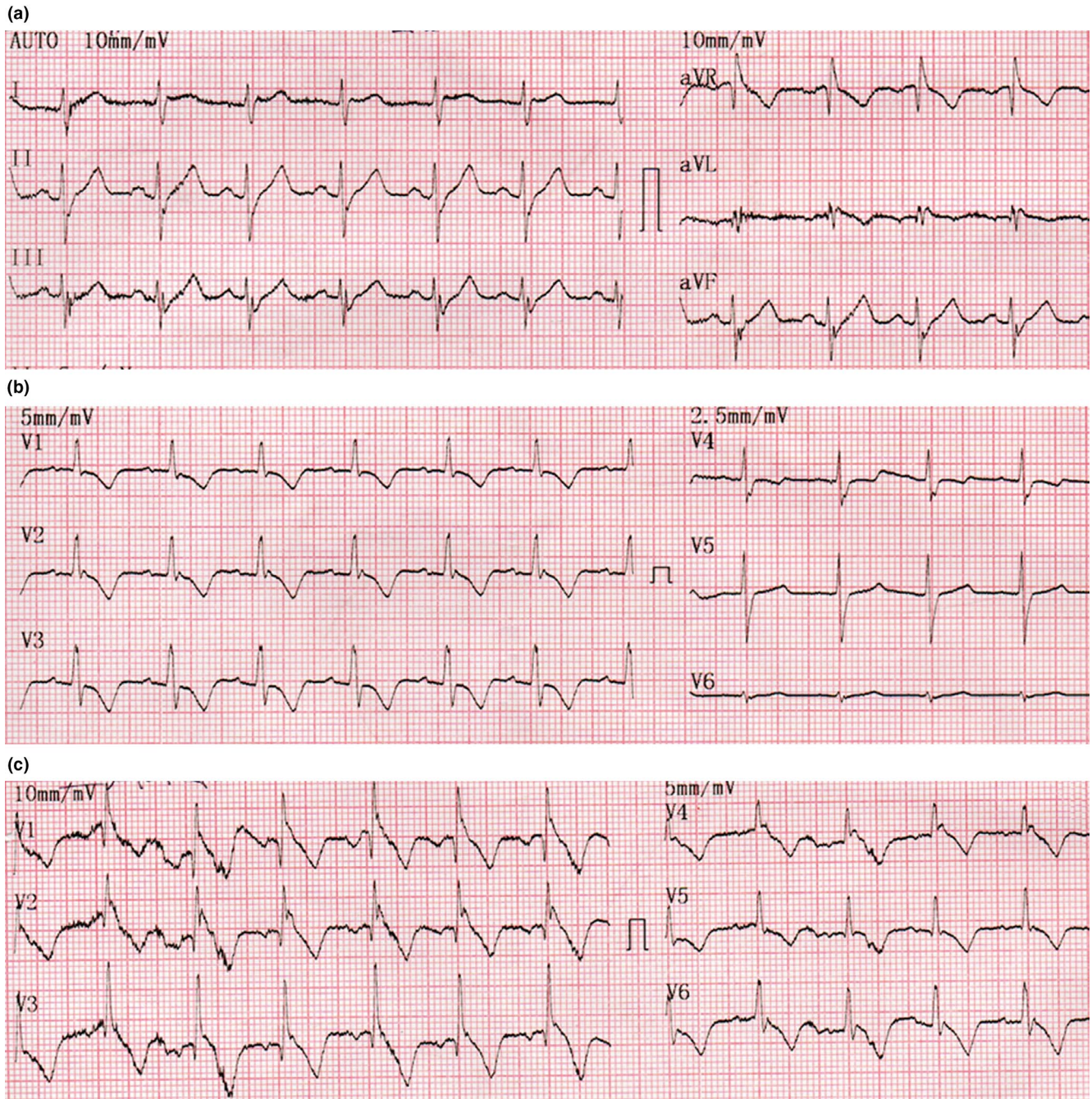


FIGURE 3 Sinus rhythm with high precordial leads (below), note J-wave elevation in aVL and high V2

recovery. In the emergency medical service, he was diagnosed with an upper respiratory tract infection. In a short period of time, he was diagnosed with a sob spasm, and repeated episodes were observed on at least five occasions within 1 year, and they were accompanied by cyanosis and diaphoresis.

Twelve hours before the current admission, he presented a new episode of flaccidity, diaphoresis, cyanosis, polypnea, seizures, and prolonged hypothermia (approximately 3 hr) with spontaneous improvement. In the following morning, the parents noticed prolonged symptoms (several hours) of diaphoresis, flaccidity, and polypnea.

The attending physician directed him to the intensive care unit, where the ECG-1 (Figure 1) was performed. It showed ventricular tachycardia. Propranolol 30 mg orally was administered. After 30 min, during the placement of a central catheter the ECG-2 (Figure 2) was performed, and it showed reversal of the tachyarrhythmia observed in ECG-1. The nodal rhythm lasted for 8 hr, probably due to the effect of the beta-blocker. After that, sinus rhythm ensued (Figure 3). Rx thorax and echocardiogram were considered normal. In the afternoon, a 12 lead 24-hr Holter was performed during a febrile peak of 38 degrees Celsius (Figure 4).

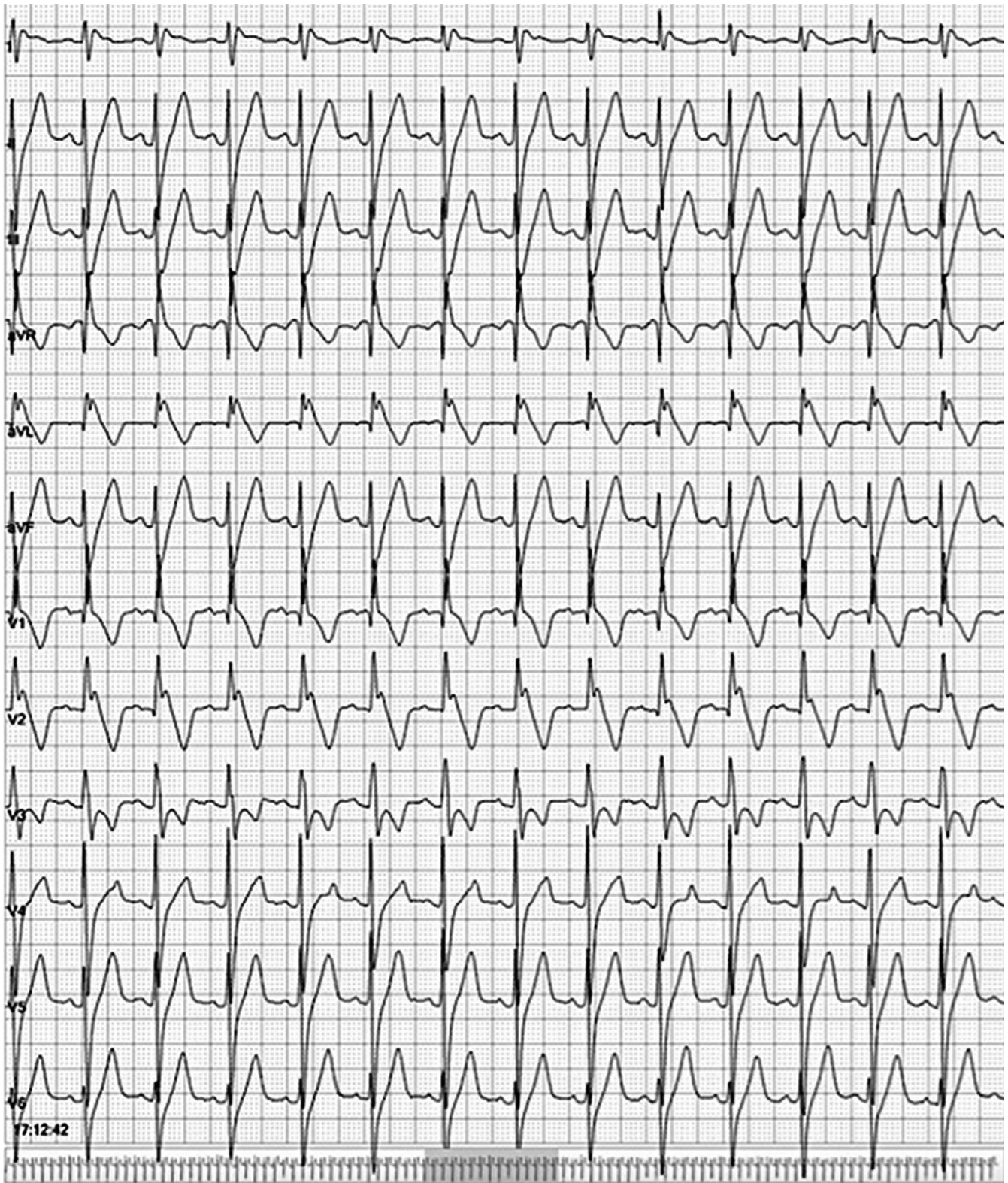

FIGURE 4 Twelve lead Holter monitoring during febrile peak (38°C), note J-wave elevation in leads I and aVL and the presence of an alternant Brugada pattern in V2

3 | DISCUSSION

BrS is an inherited arrhythmic disorder that may result in SCD. The first AE of malignant ventricular arrhythmias are documented

either at patient presentation because of aborted sudden cardiac arrest (SCA) or after prophylactic implantable cardioverter-defibrillator (ICD) implantation. The BrS ECG is much more prevalent in patients with fever than in afebrile controls with a high

prevalence in children aged 0–5 years (Adler et al., 2013). Although the risk of fever-related AE in BrS markedly varies according to age group, sex, and ethnicity, with a high prevalence of fever and AEs in the Caucasian population, where there is a high proportion of patients with an SCN5A mutation (77%) (Michowitz et al., 2018). The principal mechanism of AEs during fever is the worsening of the biophysical properties of the defective ion channels at higher temperatures, leading to further loss of function of the sodium channel current (Dumaine et al., 1999).

The Brugada type 1 pattern and the early repolarization pattern (ERP) are two ECG patterns characterized by the existence of J waves. Some experts have argued that based on their similarities in terms of demographics, ECG signatures, and response to neuro-modulation, ERP and BrS represent parts of a continuous spectrum of phenotypic expression, and classification under the umbrella term of “J-wave syndrome” was proposed (Antzelevitch & Yan, 2010). Inferolateral ERP occurs relatively frequently spontaneously in BrS, and these patients have a more severe phenotype (Kawata et al.,). Class I antiarrhythmic drug (AAD) administration provokes an inferolateral coved BrS pattern in 4.6% of patients (Sarkosy et al., 2009). Our case showed a rare presentation of J-wave elevation in leads I and aVL in association with the Br pattern in V1, V2, and in high V2.

In young patients, the presence of the spontaneous Brugada type 1 ECG pattern and symptoms at diagnosis are predictors of life-threatening arrhythmias (LTA). The management of BrS should be age-specific, and prevention of SCD may involve genetic testing and aggressive use of antipyretics and quinidine, with risk-specific consideration for ICD implantation (Andorin et al., 2016). Provocative drug testing during childhood had a low yield for predicting future AEs and was associated with serious complications in some patients. In addition, Conte et al (Conte et al., 2014) found that in 23% of children (aged 11.4 ± 2.5 years) with a negative ajmaline challenge test, BrS will be unmasked when the test is repeated several years later (age, 20.9 ± 4.2 years). Therefore, in asymptomatic patients with periodical normal ECG, adopting a cutoff of 16 years for sodium channel blocker challenge would be reasonable and in agreement with the cutoff of 15 years suggested by Andorin et al (Andorin et al., 2016). Quinidine can be used safely until adult age and posture are achieved. Quinidine also proved to be effective during relatively short follow-up and can be proposed as a valid alternative or as a bridge to ICD implantation (Probst et al., 2007). Concomitant epicardial right ventricular outflow tract ablation and ICD implantation with epicardial leads can be a safe, feasible, and effective approach for symptomatic BrS patients (de Asmundis et al., 2018). ICD therapy is an effective strategy in young patients with symptomatic BrS, treating potentially lethal arrhythmias in >25% of patients during follow-up. Appropriate shocks were significantly associated with previously aborted SCD and spontaneous type I ECGs. However, 20% of the patients experienced inappropriate shocks. Of these, 29% were secondary

to supraventricular tachycardia, 42% to lead fracture and 29% to T-wave oversensing (Gonzalez Corcia et al., 2018).

4 | CONCLUSIONS

We present a young boy, who probably had ventricular tachycardia associated with fever since 1 year of age. The ECG presentation was special with ERP in leads I and aVL and BrS-type spontaneous ST elevation during fever in V1 and V2. This is, to our knowledge, the first case with this special ECG presentation in a small child.

ORCID

Humberto Rodriguez-Reyes  0000-0003-3164-8515

Andrés Pérez-Riera  0000-0003-4948-538X

REFERENCES

- Adler, A., Topaz, G., Heller, K., Zeltser, D., Ohayon, T., Rozovski, U., ... Viskin, S. (2013). Fever-induced Brugada pattern: How common is it and what does it mean? *Heart Rhythm: the Official Journal of the Heart Rhythm Society*, 10(9), 1375–1382.
- Andorin, A., Behr, E. R., Denjoy, I., Crotti, L., Dagradi, F., Jesel, L., ... Probst, V. (2016). Impact of clinical and genetic findings on the management of young patients with Brugada syndrome. *Heart Rhythm: the Official Journal of the Heart Rhythm Society*, 13(6), 1274–1282.
- Antzelevitch, C., & Yan, G.-X. (2010). J wave syndromes. *Heart Rhythm: the Official Journal of the Heart Rhythm Society*, 7(4), 549–558.
- Conte, G., de Asmundis, C., Ciconte, G., Julià, J., Sieira, J., Chierchia, G.-B., & Brugada, P. (2014). Follow-up from childhood to adulthood of individuals with family history of Brugada Syndrome and normal electrocardiograms. *JAMA*, 312(19), 2039.
- de Asmundis, C., Chierchia, G. B., Baltogiannis, G. G., Salghetti, F., Sieira, J., Kolettis, T. M., ... La Meir, M. (2018). Concomitant Brugada syndrome substrate ablation and epicardial abdominal cardioverter-defibrillator implantation in a child. *Heart Rhythm Case Reports*, 4(6), 214–218.
- Dumaine, R., Towbin, J. A., Brugada, P., Vatta, M., Nesterenko, D. V., Nesterenko, V. V., ... Antzelevitch, C. (1999). Ionic mechanisms responsible for the electrocardiographic phenotype of the Brugada syndrome are temperature dependent. *Circulation Research*, 85(9), 803–809.
- Gonzalez Corcia, M. C., Sieira, J., Pappaert, G., de Asmundis, C., Chierchia, G. B., La Meir, M., ... Brugada, P. (2018). Implantable cardioverter-defibrillators in children and adolescents with Brugada Syndrome. *Journal of the American College of Cardiology*, 71(2), 148–157.
- Kawata, H., Morita, H., Yamada, Y., Noda, T., Satomi, K., Aiba, T., ... Shimizu, W. (2013). Prognostic significance of early repolarization in inferolateral leads in Brugada patients with documented ventricular fibrillation: A novel risk factor for Brugada syndrome with ventricular fibrillation. *Heart Rhythm: the Official Journal of the Heart Rhythm Society*, 10(8), 1161–1168.
- Michowitz, Y., Milman, A., Sarquella-Brugada, G., Andorin, A., Champagne, J., Postema, P. G., ... Belhassen, B. (2018). Fever-related arrhythmic events in the multicenter Survey on Arrhythmic Events

- in Brugada Syndrome. *Heart Rhythm: the Official Journal of the Heart Rhythm Society*, 15(9), 1394–1401.
- Milman, A., Andorin, A., Gourraud, J.-B., Sacher, F., Mabo, P., Kim, S.-H., ... Belhassen, B. (2017). Age of first arrhythmic event in Brugada Syndrome. *Circulation: Arrhythmia and Electrophysiology*, 10(12), e005222.
- Probst, V., Denjoy, I., Meregalli, P. G., Amirault, J. C., Sacher, F., Mansourati, J., ... Wilde, A. A. (2007). Clinical aspects and prognosis of Brugada syndrome in children. *Circulation*, 115(15), 2042–2048.
- Sarkozy, A., Chierchia, G.-B., Paparella, G., Boussy, T., De Asmundis, C., Roos, M., ... Brugada, P. (2009). Inferior and lateral electrocardiographic repolarization abnormalities in Brugada Syndrome. *Circulation: Arrhythmia and Electrophysiology*, 2(2), 154–161.

How to cite this article: Humberto R-R, Andrés P-R, López BL, et al. Repetitive syncopal episodes in a child with documented ventricular tachycardia, early repolarization pattern in leads I and aVL, Brugada syndrome, and fever. *Ann Noninvasive Electrocardiol*. 2019;e12698. <https://doi.org/10.1111/anec.12698>